

## Childhood neuro-motor disorders treated with silica-rich mineral water: A case report

Tullio Grassi

Faculty Specialist, Dept. of Physics, University of Maryland, USA

**\*Corresponding Author: Tullio Grassi**

Email: [tgrassi@umd.edu](mailto:tgrassi@umd.edu)

### Abstract

Previous works have shown the benefits of drinking silica-rich mineral water by patients diagnosed with specific neurological diseases. The suggested mechanism is that silica-rich water facilitates the removal of aluminum from the body and the nervous system. This report describes the case of a child with a mix of neurological and motor symptoms that have greatly decreased while drinking silica-rich water over a period of less than one year. These improvements also show a correlation with EEG results. A discussion of potential sources of aluminum that the child was exposed to is also included.

**Keywords:** Child, Neurological disorders, Motor skills, Seizures, Silicon, Aluminum.

### Case Report

A previously healthy male child, between three or four years of age, started to present the following symptoms: shaking repeatedly his head left and right as if to say "no", pain in the legs without apparent reason, chronic cough during sleeping time without symptoms of either a cold or a gastroesophageal reflux disease. These symptoms were not of sufficient concern to be reported to doctors.

When the child reached 52-months of age, new, more serious symptoms appeared including episodes of full-body involuntary movements and absence seizures that included not responding to words and appearing confused or in a haze. Each of these episodes typically had a duration of less than a minute. The child was taken to the emergency room of a children's university hospital in Switzerland. The family had taken video recordings of the movements and these were shown to doctors.

Full-body involuntary movements were of two types: one type was walking in a repetitive pattern, while making anomalous movements of hands, arms, feet. The other type happened when the child was either in bed or on a similarly flat surface. In this type, the movement was starting from a knee-elbow position, then the child suddenly pushed his legs making a small horizontal jump and often hitting his head on obstacles in front of him.

There is no family history of neurological disorders. The child's two parents and four grandparents have never been diagnosed with neurological disorders.

After the appearance of more serious symptoms, these symptoms were more carefully observed and recorded in a journal. The following three additional anomalies were noted:

1. During sleep the child had shaking and tremors of body parts, the tremors were not visible by eye but was very clear by touching the child, and these tremors typically happened in bursts;
2. While awake, for a period of less than a minute, the child did not respond to words and did not remember appealing words told to him (the word "chocolate" was normally used);
3. While awake, for a period of less than a minute, strange smiling expressions with no apparent reason.



The last two symptoms observed when the child was awake seem similar to absence seizures.

During a 24-hour period the child had an average of about seven involuntary full-body episodes, and a higher amount of episodes with the other anomalies. In the subsequent months the child was able to explain that during these episodes, his arms or legs were moving by themselves and he did not like that; on the contrary he liked the left-right head shaking. When he had a strange smiling expression, he denied he was smiling. During the period with maximum symptoms (age 52 and 53 months) the child showed increased tiredness and problems of loss of balance when walking, running, playing, in moments when apparently he was not having the episodes previously described. The episodes were rare when the child was focused on a task he liked.

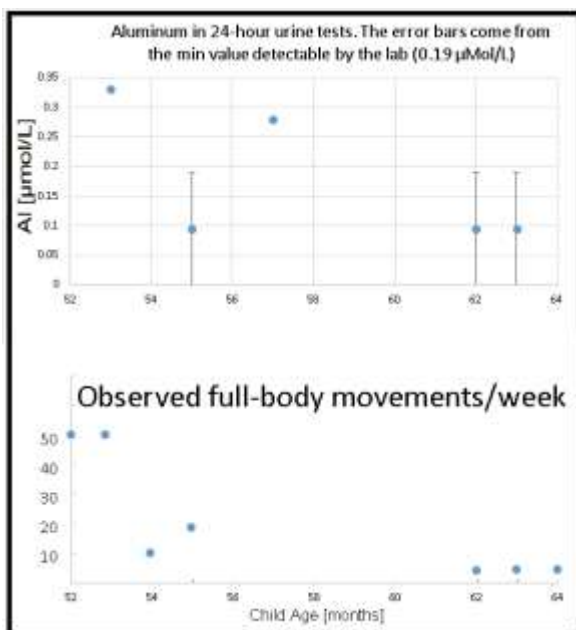
A 40-minute video-EEG was done 3 days after the visit at the emergency room and revealed epileptiform patterns (spike waves in the left back area of the brain). Initial report from the neurology department described them as focal epilepsy. Five days later, an 18-hour video-EEG was done. Reports from these two EEGs agreed. However, later analysis of the video recordings done during the EEGs showed that the spike waves events did not correspond to any anomalous body movement. At this point the hypothesis of focal epilepsy was discarded.

Magnetic resonance imaging (MRI) did not show any anomaly. Blood, urine, throat swab direct tests and cultures were performed in order to investigate a hypothesis of PANDAS. The tests did not reveal any sign of infection (including Streptococcus Groups A, C, G), and did not show anomalies with Anti-NMDA-Receptors.

Child neurologists from three different hospitals have seen the child and the test results. They all agreed that the child had one or more neurological disorders, and they considered various diseases including epilepsy, PANDAS,

complex tics, stereotyped movements, but they did not confirm any of these diagnoses.

A change in the diet was introduced, replacing as much as possible tap water with silica-rich mineral water, based on positive results with this type of mineral water on various neurological diseases.<sup>1,2</sup> The mineral waters used for this case were first the commercially available brand Carrefour Eau d'Auvergne, that is no longer available, and second Volvic, both with a content of 32 mg/l of silica (SiO<sub>2</sub>). Family members administered the silicon-rich water as much as possible, however when the child was at pre-school or school (about 9 hours per day, on normal school days) he continued drinking tap water. The child has maintained this pattern of water intake to date. When the child started drinking silica-rich mineral water he had also stopped drinking infant formulas and started to have a more varied diet. After two months of these changes in diet, the child's symptoms started to diminish. After eight months of this new diet, the involuntary full-body movements were reduced from the initial value of about 50 per week to about 5 per week (Fig. 1). A similar reduction was observed for the other symptoms, including the chronic cough and absence seizure frequency.



**Fig. 1:** Evolution over time of aluminum excretions and episodes of full-body involuntary movements. EEG at 52 months of age showed epileptiform anomalies. Drinking of silica-rich water started at 52.5 months. EEG at 64 months showed normal results (no anomalies).

Several urine analyses were performed in order to measure the amount of aluminum excreted. The results are plotted in figure. The plot shows that the aluminum content of the urine has decreased to a level below the detection capability of the laboratory. This trend follows the decrease in the neuro-disorders of the child. Another EEG was performed at the age of 64 months and it was normal (no anomalies). The

child has never used any neurological drug, and he has not used any drug on a regular basis.

## Discussion

For this case, it has not been possible to formulate a clear diagnosis based on documented diseases, and this has motivated further investigations. Medical literature<sup>4,5</sup> and clinical experience show that it is not rare to have neurological disorders appearing in children around 5 year of age, and gradually declining during adolescence. In this case, the symptoms were greatly reduced within less than a year. This relatively fast evolution suggests that aluminum accumulation causes neuro-disorders and drinking silicon-rich water can cure these disorders.

Aluminum has no useful role in human beings and animals and is a known neuro toxic element.<sup>3</sup> This case report shows that aluminum was present in the body, and implies that silicon-rich water facilitated the removal of some of it. During this removal process, the child's neuro-disorders, chronic cough and EEG results improved. Another implication is that the chronic cough of this case seems to be of neurological origin,<sup>6</sup> as the other common causes (cold, gastroesophageal reflux disease) did not match the symptoms.

Potential sources of aluminum that the child was exposed to were examined. Sources of aluminum reported in literature are: tap water,<sup>7</sup> infant formulas,<sup>8</sup> other processed foods,<sup>9</sup> vaccines.<sup>3,10</sup> Of these potential sources, tap water from the house where the child has lived was tested and showed a content of aluminum of 6.8 µg/l, which is well within regulations and this content excludes tap water from the significant sources of aluminum. The only processed food that he had on a regular basis were infant formulas (Aptimal brand). Mitkus et al.<sup>11</sup> estimated the body burden of aluminum during the first 400 days of life for infants on formula diets and for a standard vaccination schedule, and the estimates show that the burden of aluminum from vaccinations exceeds that from dietary sources.<sup>11</sup> The child's aluminum containing vaccinations were: Infanrix DTPa-IPV+Hib (4 doses at 500 µg aluminum per dose), Prevenar13 (3 doses at 125 µg aluminum per dose), NeisVac-C Baxter (1 dose at 500 µg aluminum per dose). The child was also vaccinated with Priorix (2 doses) but this vaccine does not contain an aluminum adjuvant.

Aptimal First Milk powdered infant formulas have been tested for aluminum and found to result in the ingestion of 124 µg of aluminum per day on average.<sup>8</sup> Aptimal Follow On powdered infant formulas were also tested and found to result in the ingestion of 137 µg of aluminum per day on average.<sup>8</sup> Unlike vaccinations that are 100% bioavailable, only 0.2% (0.25 to 0.27 µg) of the aluminum per day is estimated on average to be absorbed by the gut from these Aptimal formulas and made bioavailable to a child's body.<sup>12</sup>

After four years on these infant formulas the child absorbed approximately 390 µg of aluminum, while the total amount of aluminum added to the child's body by vaccinations is estimated to be 2875 µg.

## Conclusions

The presented case suggests that aluminum can be a cause of child intoxication. Moreover, it shows that silica-rich mineral water can be used as a treatment for these cases.

**Source of Funding:** None.

**Conflicts of Interest:** None.

## References

1. Exley C, Mamutse G, Korchazhkina O, Pye E, Strekopytov S, Polwart A, et al. Elevated urinary excretion of aluminium and iron in multiple sclerosis. *Mult Scler* 2006;12(5):533–40.
2. Davenward S, Bentham P, Wright J, Crome P, Job D, Polwart A, et al. Silicon-rich mineral water as a non-invasive test of the “aluminum hypothesis” in Alzheimer’s disease. *J Alzheimers Dis* 2013;33(2):423–30.
3. Shaw CA, Tomljenovic L. Aluminum in the central nervous system (CNS): toxicity in humans and animals, vaccine adjuvants, and autoimmunity. *Immunol Res* 2013;56(2–3):304–16.
4. Gillberg IC, Gillberg C, Groth J. Children with preschool minor neurodevelopmental disorders. V: Neurodevelopmental profiles at age 13. *Dev Med Child Neurol* 1989;31(1):14–24.
5. Groth C. Tourette syndrome in a longitudinal perspective. Clinical course of tics and comorbidities, coexisting psychopathologies, phenotypes and predictors. *Dan Med J* 2018;65(4).
6. Niimi A, Chung KF. Evidence for neuropathic processes in chronic cough. *Pulm Pharmacol Ther* 2015;35:100–4.
7. Rondeau V, Commenges D, Jacqmin-Gadda H, Dartigues J-F. Relation between Aluminum Concentrations in Drinking Water and Alzheimer’s Disease: An 8-year Follow-up Study. *Am J Epidemiol* 2000;152(1):59–66.
8. Chuchu N, Patel B, Sebastian B, Exley C. The aluminium content of infant formulas remains too high. *BMC Pediatr* 2013;13:162.
9. Sato K, Suzuki I, Kubota H, Furusho N, Inoue T, Yasukouchi Y, et al. Estimation of daily aluminum intake in Japan based on food consumption inspection results: impact of food additives. *Food Sci Nutr* 2014;2(4):389–97.
10. Shardlow E, Mold M, Exley C. Unraveling the enigma: elucidating the relationship between the physicochemical properties of aluminium-based adjuvants and their immunological mechanisms of action. *Allergy Asthma Clin Immunol* 2018;14:80.
11. Mitkus RJ, King DB, Hess MA, Forshee RA, Walderhaug MO. Updated aluminum pharmacokinetics following infant exposures through diet and vaccination. *Vaccine* 2011 Nov 28;29(51):9538–43.
12. Yokel RA, McNamara PJ. Aluminium toxicokinetics: an updated minireview. *Pharmacol Toxicol* 2001;88(4):159–67.

**How to cite this article:** Grassi T. Childhood neuro-motor disorders treated with silica-rich mineral water: A case report. *J Prev Med Holistic Health* 2019;5(1):70-72.