

## SUCCESSFUL POVIDONE-IODINE PLEURODESIS IN A CASE OF RECURRENT PLEURAL EFFUSION DUE TO METASTATIC ADENOCARCINOMA OF LUNG

Manoranjan Dash<sup>1,\*</sup>, Jyoti Patnaik<sup>2</sup>, Thitta Mohanty<sup>3</sup>,  
Sweta Padma Pradhan<sup>4</sup>, Saswat Subhankar<sup>5</sup>, Vijay Aravindh.R.<sup>6</sup>

<sup>1</sup>Assistant Professor, <sup>2</sup>Professor, <sup>3</sup>Associate Professor, <sup>4</sup>Senior Resident, <sup>5,6</sup>Junior Resident,  
Department of Pulmonary Medicine, SCB Medical College, Cuttack, Odisha.

**\*Corresponding Author:**  
E-mail: drmrddash@reddifmail.com

### ABSTRACT<sup>[1]</sup>

Chemical pleurodesis is an effective treatment for recurrent malignant pleural effusion. Though many drugs and chemical agents have been approved,<sup>[3][5]</sup> Iodo-povidone is a topical antiseptic and has shown to be safe, painless and effective agent for pleurodesis. Here we present a case of recurrent pleural effusion due to metastatic adenocarcinoma who had been repeatedly aspirated which increased her morbidity because of repeated hospitalisation. She was treated effectively with<sup>[4]</sup> povidone iodine pleurodesis, following which, even after fourth month follow up there was no further pleural collection.

**Key words:** pleurodesis, malignant effusion, povidone

### INTRODUCTION<sup>2</sup>

Malignant pleural effusion continues to be a common problem in patients with metastatic disease, leading to significant reduction in the quality of life with progressive dyspnea, dry cough, chest pain and reduced physical activity. Repeated accumulation of pleural fluid leads to recurrent hospitalisation. So obliteration of the pleural space by povidone iodine agent seems to be an excellent agent for pleurodesis, which improves the quality of life.

### CASE STUDY

A 70 year old female was admitted with complaints of shortness of breath. Chest X ray was done (fig-1). With the diagnosis of massive left sided pleural effusion 1.5 litres of haemorrhagic pleural fluid was aspirated. Even prior to the admission she was being aspirated repeatedly by the physicians 5 to 6 times in the last 6 months. HRCT thorax showed a mass lesion with left sided massive pleural effusion. Bronchoscopy was normal. Pleural fluid cytological analysis was an exudate, proved to be adenocarcinomatous. So an intercoastal chest tube (fig 2) was given patient was referred to oncologist for further management. But unfortunately because of her low condition and old age Chemotherapy was deferred. As the patient was severely dyspnic because of the recurrent pleural accumulation, we had planned for a chemical pleurodesis with povidone-iodine. On fifth day 4.5 litre of hemorrhagic fluid was drained out and lung was expanded. So Pleurodesis was done with povidone-iodone 40 ml with 60ml of normal saline. Prior to instillation of povidone iodone 20 ml of 2% xylocaine with 30ml of normal saline was instilled in the pleural sac. Chest tube was clamped for 6hrs. On third day of the pleurodesis chest tube (fig 3) was removed and on seventh day of pleurodesis patient was

discharged. Then after that patient was followed up in every month up to the end of fourth month (fig 4 and 5). What we found was that, there was no accumulation of fluid in the pleural space and respiratory distress was decreased significantly.

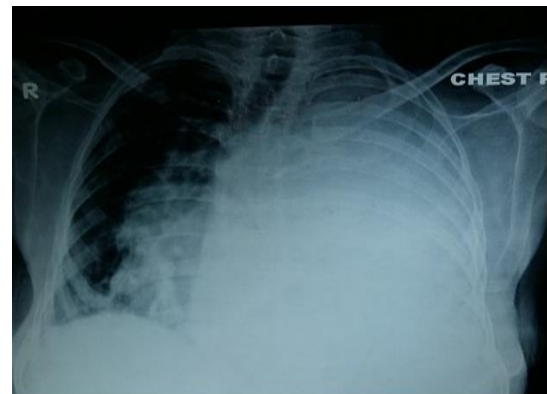


Fig.1 -ON ADMISSION

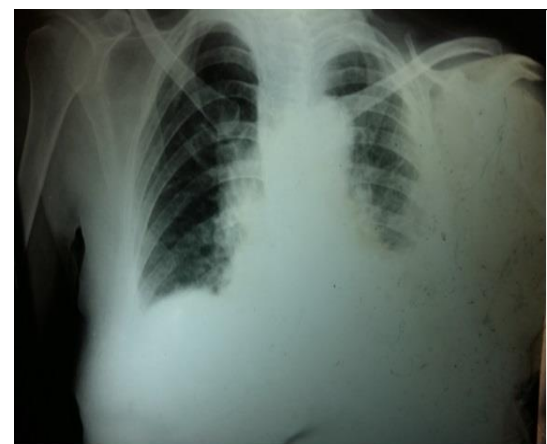

Fig.2- POST ICTD

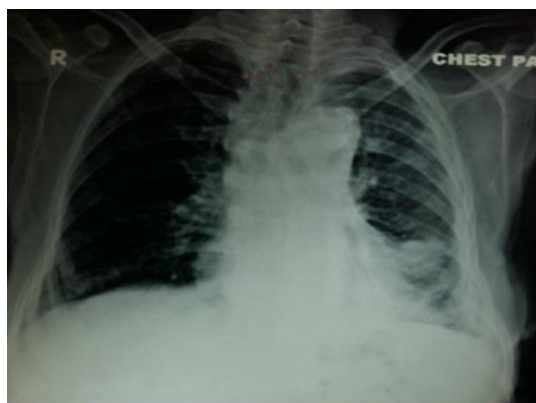


Fig.3-POST PLEURODESIS DAY 3

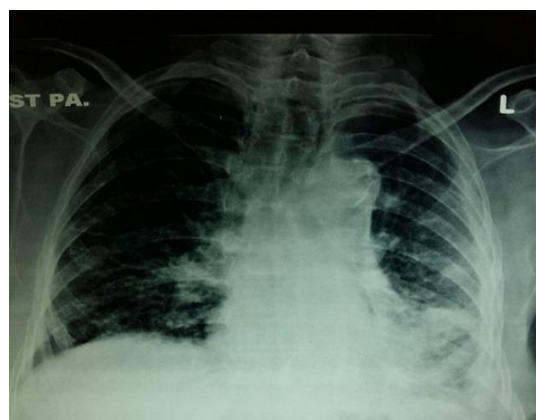


Fig.4- 2 MONTHS POST PLEURODESIS

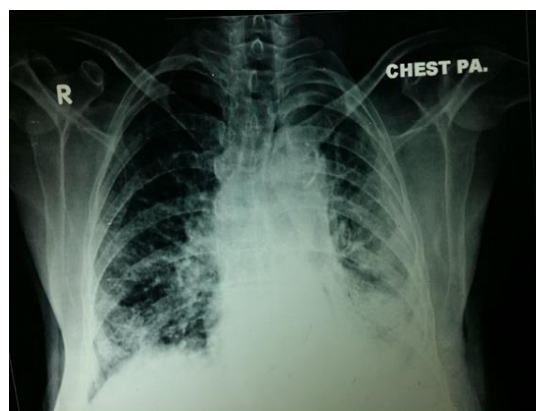


Fig 5- 4 MONTHS POST PLEURODESIS

after which chemotherapy was initiated and the patient apparently did well.

## CONCLUSION

Povidone iodine Pleurodesis can be considered for cases of recurrent malignant pleural effusion as it is safe, cost effective and feasible.

## REFERENCES

1. Olivares-Torres CA<sup>1</sup>, Laniado-Laborín R, Chávez-García C, León-Gastelum C, Reyes-Escamilla A, Light RW. Iodopovidone pleurodesis for recurrent pleural effusions. *Chest*. 2002 Aug; 122(2):581-3.
2. Ibrahim IM<sup>1</sup>, Dokhan AL<sup>2</sup>, El-Sessy AA<sup>3</sup>, Eltaweel MF<sup>4</sup> Povidone-iodine pleurodesis versus talc pleurodesis in preventing recurrence of malignant pleural effusion. *J Cardiothorac Surg*. 2015 May 1; 10(1):64. doi: 10.1186/s13019-015-0270-5.
3. Godazandeh G<sup>1</sup>, Qasemi NH, Saghafi M, Mortazian M, Tayebi P. Pleurodesis with povidone-iodine, as an effective procedure in management of patients with malignant pleural effusion. *J Thorac Dis*. 2013 Apr; 5(2):141-4. doi: 10.3978/j.issn.2072-1439.2013.02.02.
4. Alavi AA<sup>1</sup>, Eshraghi M, Rahim MB, Meysami AP, Morteza A, Hajian H. Povidone-iodine and bleomycin in the management of malignant pleural effusion. *Acta Med Iran*. 2011;49(9):584-7.
5. Agarwal R<sup>1</sup>, Aggarwal AN, Gupta D, Jindal SK. Efficacy and safety of iodopovidone in chemical pleurodesis: a meta-analysis of observational studies. *Respir Med*. 2006 Nov;100(11):2043-7. Epub 2006 Mar 30.
6. Neto JD<sup>1</sup>, de Oliveira SF, Vianna SP, Terra RM. Efficacy and safety of iodopovidone pleurodesis in malignant pleural effusions. *Respirology*. 2010 Jan;15(1):115-8. doi: 10.1111/j.1440-1843.2009.01663.x. Epub 2009 Nov 23.

## DISCUSSION

Pleurodesis is done in metastatic pleural effusion to prevent recurrent accumulation of effusion and thereby of symptoms and avoid the need for repeated hospitalisation for thoracentesis. Chemotherapy could not be initiated for this case of metastatic adenocarcinoma because of the clinical deterioration of the patient because of the recurrent accumulation of the fluid. An effective pleurodesis with<sup>[6]</sup> Povidone-iodine had helped the patient to improve clinically